

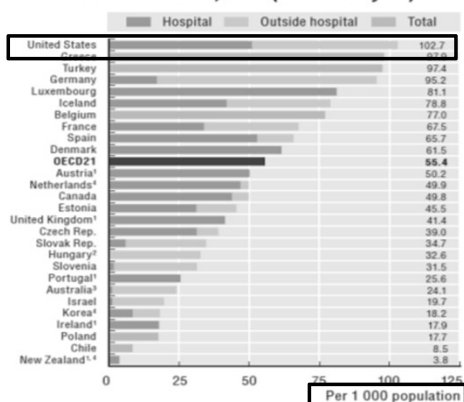
		
<h2>Hearing Implants and MRI: Issues and Safety</h2>		
<p>Darla Franz, VP Education MED-EL North America</p>	<p>Martin Zimmerling, Head of Implant R&amp;D MED-EL Headquarters</p>	

	
<h2>Why Should This Topic Matter to Audiologists?</h2>	
	
© MED-EL	

## Number of MRI vs. CT Exams

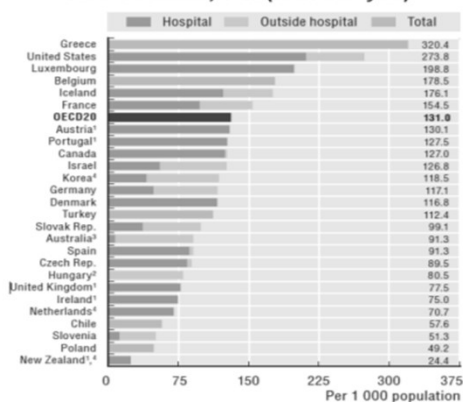
### 4.2.3. MRI exams, 2011 (or nearest year)



1. Exams outside hospital not included.
2. Exams in hospital not included.
3. Exams on public patients not included.
4. Exams privately-funded not included.

Source: OECD Health Statistics 2013, <http://dx.doi.org/10.1787/health-data-en>.  
StatLink <http://dx.doi.org/10.1787/888932917294>

### 4.2.4. CT exams, 2011 (or nearest year)

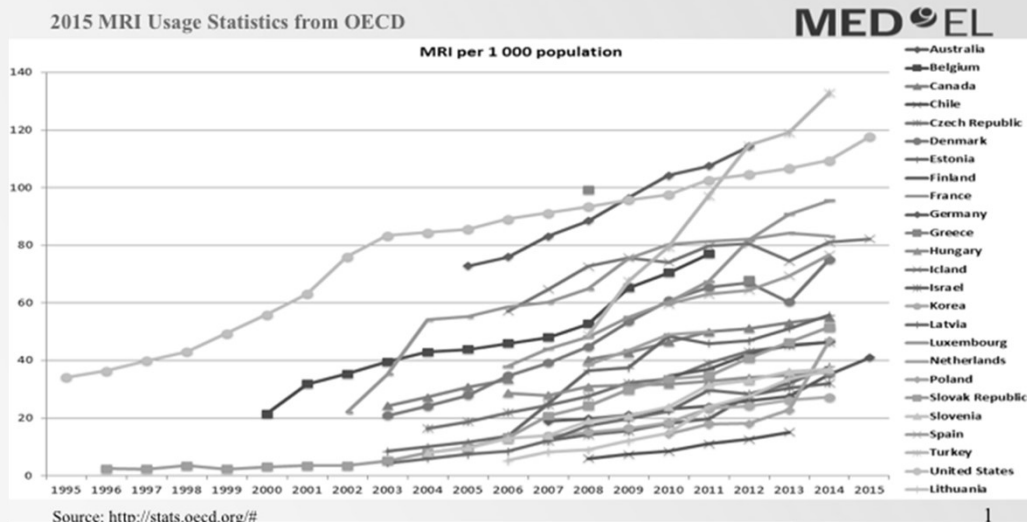


1. Exams outside hospital not included.
2. Exams in hospital not included.
3. Exams on public patients not included.
4. Exams privately-funded not included.

Source: OECD Health Statistics 2013, <http://dx.doi.org/10.1787/health-data-en>.  
StatLink <http://dx.doi.org/10.1787/888932917313>

© MED-EL

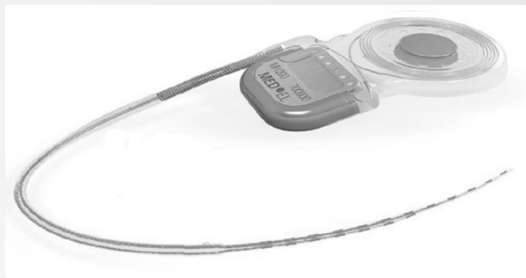## 2015 MRI Usage Statistics from OECD



© MED-EL

© MED-EL

## Possible Interactions with Implants



### ▪ Static Magnetic Field:

- Linear force and torque
- Magnet dislocation
- Demagnetization

### ▪ Radio Frequency Field:

- Voltage induction
- Unintended stimulations
- Heating (electrode contacts)

### ▪ Magnetic Gradient Fields:

- Vibrations of the implant
- Implant damage
- Unintended stimulations
- Heating (housing)

### ▪ Influence on the MRI System:

- Image artifacts

© MED-EL

## MRI with MED-EL Implants

- 2001 First FDA approval of MRI at 0.2 T with axial magnet in place for the COMBI 40+ implant
  - Required company pre-authorization
  - International approval for 0.2T, 1.0T, 1.5T with magnet in place
- 2005 PULSAR implant FDA approved for 0.2T with axial magnet in place
- 2007 SONATA implant FDA approved for 0.2T with axial magnet in place
- 2013 MED-EL CONCERT, SONATA and PULSAR implants approved for 1.5 T MRI with the axial magnet in place
  - Prior authorization requirement was lifted
- At that point, literally hundreds of scans had been completed around the world on MED-EL implants with no major reported adverse events

© MED-EL

## Recent News

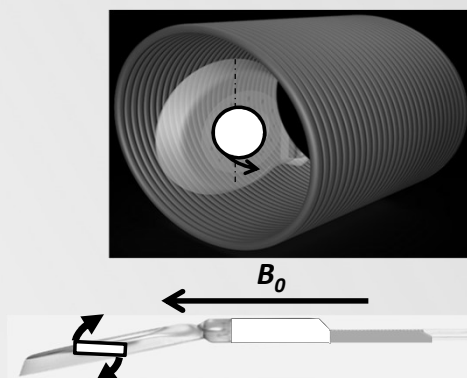
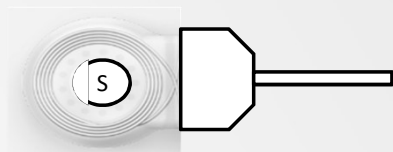
- 2015: SYNCHRONY implant with revolutionary diametric magnet approved for
  - 1.5T and 3.0T MRI with magnet in place
  - 1.5T and 3.0T MRI with magnet optionally removed
  - No pre-authorization requirement in the USA
  - Bandaging/splinting is *optional*
- 2016: Early COMBI 40+ implant received FDA approval for 1.5T MRI with axial magnet in place
  - Implanted 1998-2005 in the USA

© MED-EL

## Do All “MR Conditional” Approved Hearing Implants Behave the Same in MRI?

- Implant magnet design and fixation is the key to MRI safety

Some CIs with axial magnets placed in a silicone pocket:

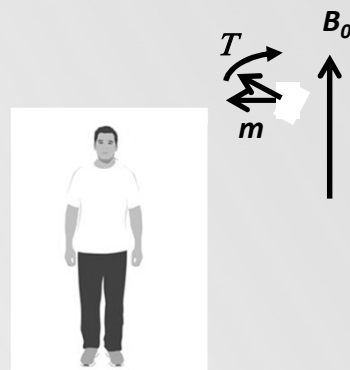


© MED-EL

## Magnet Design for SONATA and CONCERT

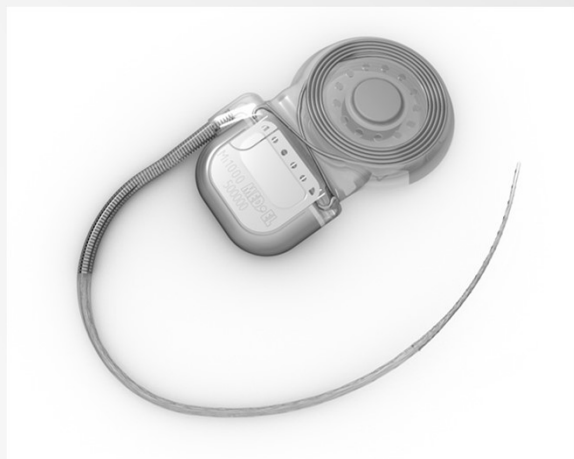Torque = in standard position the magnet is nearly perpendicular to  $B_0$ . Torque is exerted, trying to align the magnet

Demagnetization = If the magnet cannot align, there is a risk of the magnet weakening



© MED-EL

## Design Feature to Reduce Pressure Footprint




Magnet fixation disc distributes lever arm force when torque is exerted

- Large pressure footprint with **very little pressure**
- Feature of all MED-EL titanium housing Implants

© MED-EL

## Pressure Footprint During MRI



For comparison:

**What would happen without a magnet fixation disc:**

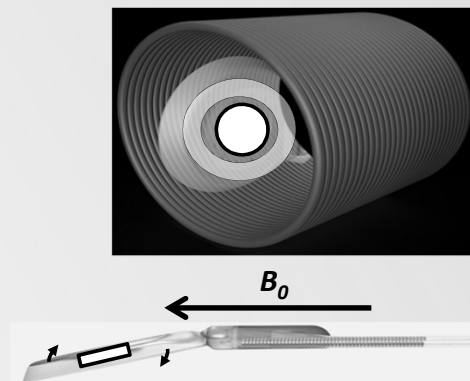

There would be a pronounced, punctual pressure footprint.

© MED-EL

## Do All “MR Conditional” Approved Hearing Implants Behave the Same in MRI?

- Implant magnet design and fixation is a key to MRI safety

SONATA, CONCERT: with axial magnet and magnet fixation disc



12

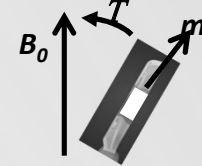
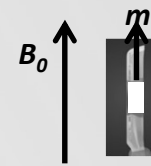
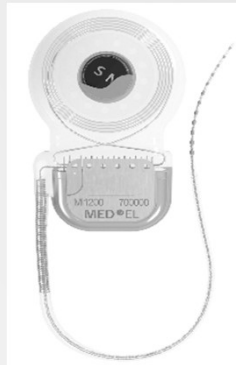
© MED-EL

## SYNCHRONY Implant Optimized for MRI

### NEW! Diametrical Magnetization

Torque = in standard position the magnet can almost perfectly align with  $B_0$ , even if patient turns head to the side. Only if the patient tilts head to the side (not a typical MRI orientation) would torque be present.

Demagnetization = zero





© MED-EL

## Do All “MR Conditional” Approved Hearing Implants Behave the Same in MRI?

- Implant magnet design and fixation is a key to MRI safety


SYNCHRONY with diametrical magnet and fixation disk:



14

© MED-EL

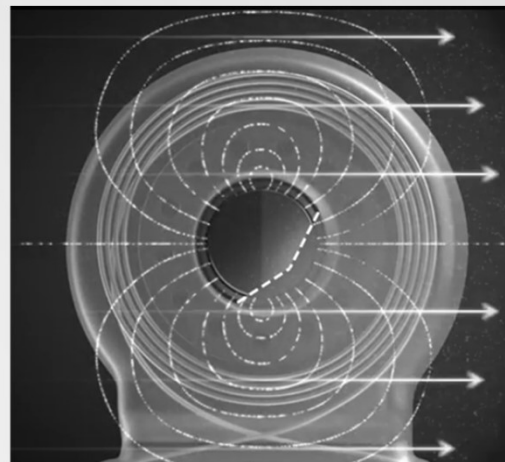

## Self-Adjusting Magnet Optimized for MRI



- Diametrically magnetized internal magnet
- Placed to freely rotate in hermetic housing
- Aligns parallel to magnetic field
  - Implant magnet never weakens
  - Torque is close to zero
- Addresses increasing popularity of 3.0T scanners
- Patented design

© MED-EL

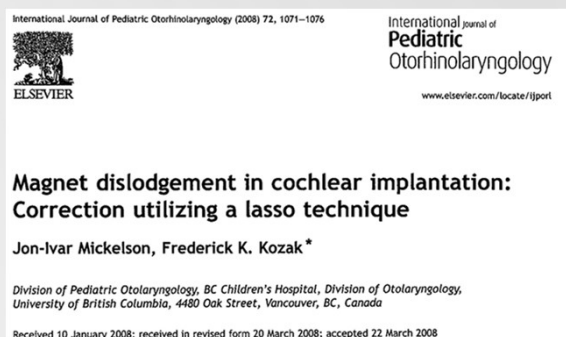## Why Does It Matter?



© MED-EL

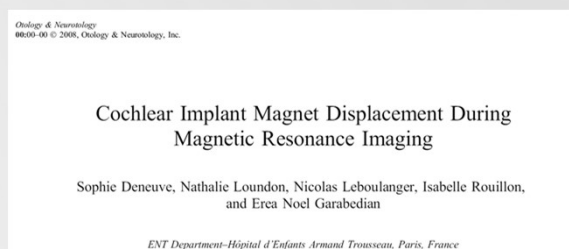
## Spontaneous Magnet Displacement

- BC Mickelson et al 2008: Child with minor head trauma resulting in magnet dislocation, then suffered a repeat dislocation after being hit with a snowball. AB device.
- Reported that 50 dislocations had been experienced (cited industry) and one other repeat dislocation



## Magnet Dislodged During MRI

- 2008 Paris Deneuve et al
- Child with Cochlear device underwent successful MRI. 2<sup>nd</sup> MRI a year later resulted in pain, burning. Both MRIs followed manufacturer's instructions re compression dressing
- Two weeks later the patient developed pain and edema, magnet was found to be out of the pocket.



## Spontaneous Magnet Displacement

- 2009 Swiss case report of 3 Cochlear patients who had spontaneous magnet dislocation
  - Magnetic toys that were placed near the implant
  - Impact resulting in dislocation of the magnet
- Authors suggest no longer implanting children with removable magnets!

Eur Arch Otorhinolaryngol  
DOI 10.1007/s00405-009-1017-5

OTOLOGY

### Magnet displacement: a rare complication following cochlear implantation

Corina Wild · John Allum · Rudolf Probst ·  
Daniel Abels · Claude Fischer · Daniel Bodmer

© MED-EL

## Magnet Reversal

- 2011 Korea
- AB patient presented with opposite magnet polarity after 2<sup>nd</sup> 1.5T MRI with magnet in place (head bandage was used)
- Patient reported temporary sensation of magnet on end



Auris Nasus Larynx xxx (2011) xxx–xxx

AURIS NASUS  
LARYNX  
INTERNATIONAL JOURNAL  
OF OTOLOGY

www.elsevier.com/locate/auris

### Reversing the polarity of a cochlear implant magnet after magnetic resonance imaging

Ju Hyun Jeon, Mi Ran Bae, Jae Won Chang, Jae Young Choi<sup>®</sup>

Department of Otorhinolaryngology, Yonsei University College of Medicine, 134 Sinchon-dong, Seodaemun-gu, Seoul 120-752, Republic of Korea  
Received 29 March 2011; accepted 22 April 2011

- Authors surmise the magnet flipped in its pocket during the scan

© MED-EL

## Magnet Dislodged During MRI

- 2012 Rome
- Patient underwent MRI without contacting clinic, and without dressing
- Magnet flipped on end, and stayed that way
- Surgeon successfully manipulated magnet back into pocket through the skin

The Laryngoscope  
© 2012 The American Laryngological,  
Biological and Otolaryngological Society, Inc.

### Case Report

#### Noninvasive Management of Cochlear Implant's Inner Magnet Displacement after Magnetic Resonance: A Case Report

Walter Di Nardo, MD; Sara Giannantonio, MD; Lorenzo Schinaia, PhD; Eugenio De Corso, MD; Gaetano Paludetti, MD

© MED-EL

## Magnet Dislodged After MRI

- 2013 CI International Journal, Manchester UK
- Patient with bilateral Cochlear devices
- Pain bilaterally during scan, but images were obtained. 10 days later patient presented with bilateral skin reactions and left magnet displacement. Both magnets were eventually permanently removed for serial scanning.

### Case report

#### Cochlear implants and magnetic resonance scans: A case report and review

Stephen J Broomfield<sup>1</sup>, Melville Da Cruz<sup>2</sup>, William P R Gibson<sup>2</sup>

<sup>1</sup>Manchester Cochlear Implant Centre, Manchester, UK, <sup>2</sup>Sydney Cochlear Implant Centre, Sydney, Australia

© MED-EL



## Retrospective Review: Adverse Events

- 2014 Kim et al Korea
- 18 patients in MRI at various locations / one or multiple scans (30 scans)
- 3 MED-EL patients (one had 4x brain scans + 2 lumbar spine scans). Remaining 15 patients all with “pocket” removable magnet designs (2 CC patients had 3.0T scans)
  - 8 / 15 had pain or discomfort during MRI
  - 5 / 15 MRI couldn't be completed due to pain and discomfort
  - 1 case each of magnet dislocation and magnet reversal
- All scans were uneventful for patients with MED-EL CI

### Adverse Events and Discomfort During Magnetic Resonance Imaging in Cochlear Implant Recipients

Bo Gyoung Kim, MD, PhD, Jin Won Kim, MD, Jaegong Jin Park, MD, Sung Huh Kim, MD, PhD,

Hee Nam Kim, MD, PhD, Joo Young Choi, MD, PhD

*JAMA Otolaryngol Head Neck Surg.* doi:10.1001/jamaoto.2014.2926  
Published online November 20, 2014.

Table 1. Characteristics of the CI Recipients

Patient No./Sex/Age at CI, y	CI Device*	MRI Site	Reason for MRI	MRI Machine*	MRI Field Strength
1/M/24	Nucleus CI 24RE(CA)	Knee	Degenerative osteoarthritis	Philips Achieva	1.5 T
2/F/25	Nucleus CI 24RE(CA)	Lumbar spine (+2)	Malignant ependymoma, spinal cord	Philips Achieva	1.5 T
3/M/17	Nucleus CI 24RE(CA)	Knee (+3)	Ruptured anterior cruciate ligament	Philips Achieva	1.5 T
4/M/1	Nucleus CI 24RE(CA)	Brain	Bacterial meningitis	Philips Achieva	1.5 T
5/F/17	Nucleus CI 22M	Knee	Tear of discoid lateral meniscus	Discovery MR750	3.0 T
6/F/66	Nucleus CI 24RE(CA)	Brain	Traffic crash	Philips Achieva	1.5 T
7/F/54	Nucleus CI 24RE(CA)	Cervical spine	Traffic crash	Philips Achieva	1.5 T
8/F/66	Nucleus CI 24RE(CA)	Brain	Optic neuritis	Philips Achieva	1.5 T
9/F/38	Nucleus CI 22M	Shoulder	Chronic pain	Philips Achieva	3.0 T
10/F/11	Nucleus CI 512	Whole spine	Thoracic scoliosis	Philips Achieva	1.5 T
11/F/25	Clarion CII	Thigh	Degenerative osteoarthritis	Philips Achieva	1.5 T
12/M/2	Clarion CII	Brain	Preoperative evaluation before ABI	Philips Achieva	1.5 T
13/F/65	Clarion HiRes 90K	Right knee Left knee Lumbar spine	Degenerative osteoarthritis	Magnetom Essenza	1.5 T
14/M/4	Clarion HiRes 90K	Brain	Preoperative evaluation before ABI	Philips Achieva	1.5 T
15/M/2 (R)	Clarion CII	Brain (+3)	Diabetes insipidus	Philips Achieva	1.5 T
15/M/9 (L)	Clarion HiRes 90K	Brain (+3)	Langerhans cell histiocytosis	Philips Achieva	1.5 T
15/M/12 (R)	Nucleus CI 22	Lumbar spine (+2)	Medulloblastoma	Philips Achieva	1.5 T
16/F/6	MED-EL Combi 40+	Brain (+4) Lumbar spine (+2)	Medulloblastoma	Philips Achieva	1.5 T
17/F/60	MED-EL FLEXsoft	Thoracolumbar spine	Lumbar pain	Philips Achieva	1.5 T
18/M/35	MED-EL Pulsar	Wrist	Chronic pain	SIGNA HDxt	1.5 T

© MED-EL



## Review of Adverse Events

- 2015 Carlson et al, Mayo Clinic
- Retrospective case review of all CIs undergoing MRI between 2012-2014
- 19 ears, 34 MRI scans with bandaging and lidocaine (18 Cochlear and 1 AB)
  - 2 pts couldn't tolerate and required magnet removal
  - 1 pt experienced 2 episodes of magnet reversal, requiring surgical repositioning
  - 3 pts had canting of the magnet that was physically repositioned without surgery
  - 1 pt had 3 MRI studies with magnet removal, at 3<sup>rd</sup> surgery a tear was found in the silicone

*Otolaryngol & Neurotol.*  
© 2015, Otolaryngol & Neurotol, Inc.

### Magnetic Resonance Imaging with Cochlear Implant Magnet in Place: Safety and Imaging Quality

\*†Matthew L. Carlson, \*†Brian A. Neff, \*†Michael J. Link, ‡John I. Lane,  
‡Robert E. Watson, ‡Kieran P. McGee, ‡Matt A. Bernstein,  
and \*†Colin L. W. Driscoll

\*Departments of Otolaryngology-Head and Neck Surgery, †Neurologic Surgery, and ‡Radiology, Mayo Clinic School of Medicine, Rochester, Minnesota, U.S.A.

No difficulty seeing necessary brain structures in 94% of pts receiving head MRI

© MED-EL

## Magnet Dislocation Not Visualized on Xray

- 2016 COSM Poster
- 5 year old child sustained a minor head trauma
- Magnet's silicone pocket torn both laterally and medially, with magnet displaced *medially* and not visible on Xray due to being under the R/S
- Search of manufacturer database revealed 49 cases in a one year period (2014-2015) of dislodged magnet due to trauma

### Medial Displacement of Cochlear Implant Magnet Following Trauma

Mary Lauren Worthen, MD<sup>1</sup>; Arun Gadre, MD, FACS<sup>1</sup>;  
<sup>1</sup>Department of Otolaryngology-HNS and Communicative Disorders, University of Louisville School of Medicine

© MED-EL

680 Head/Neck

### Magnet Dislocation: An Increasing and Serious Complication Following MRI in Patients with Cochlear Implants

Magnetdislokation – eine zunehmende und folgenreiche Komplikation nach MRT bei Patienten mit Cochlea Implantat

Authors  
Affiliations

F. Hassepass<sup>1</sup>, V. Stabenau<sup>1</sup>, S. Arndt<sup>1</sup>, R. Beck<sup>1</sup>, S. Bulla<sup>2</sup>, T. Grauvogel<sup>1</sup>, A. Aschendorff<sup>1</sup>  
<sup>1</sup> Department of Otorhinolaryngology-Head and Neck Surgery, University Medical Center Freiburg  
<sup>2</sup> Department of Diagnostic Radiology, University Medical Center Freiburg

Bandage ***does not*** prevent issues with pain and discomfort

York - (T) and compression head bandage during examination.

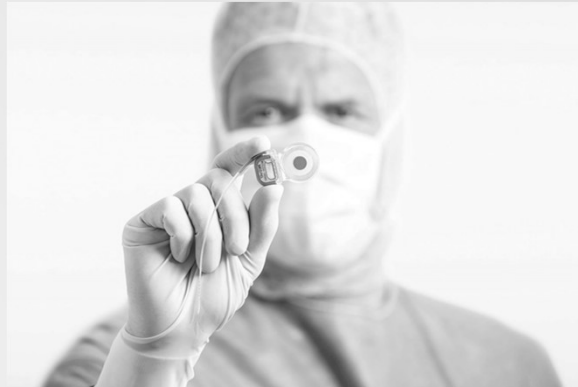Conclusion: A compression head bandage in a 1.5 T MRI unit does not safely prevent MD and the related serious complications in CI recipients. We recommend a Stenvers view radiograph after MRI with the internal magnet in place for early identification of MD, at least in the case of pain during or after MRI examination. MRI in CI patients should be indicated with restraint and patients should be explicitly informed about the possible risks. Recommendations regarding MRI compatibility and the handling of CI patients issued

gebu  
Erw  
mog  
Inzv  
schi  
sodi  
bela  
glicl  
Mag  
bei  
MR  
Mat  
wur  
zahl

© MED-EL

## The MRI Landscape Continues to Change

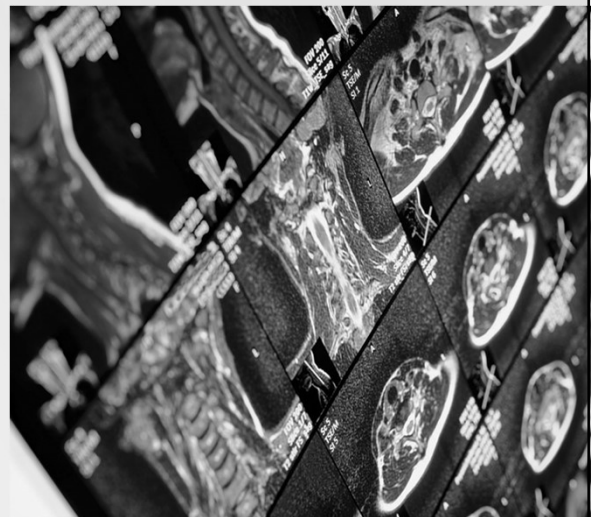- Rapidly increasing prevalence of 3.0T scanners
- Diagnostic need for increased scanner resolution
- Rapidly increasing rate of MRI usage as diagnostic tool of choice
- Clear desire from the field of medicine to make high resolution scanning more feasible
- Clear desire from recipients with significant medical issues to make MRI easier/more comfortable



© MED-EL

## Tests to Demonstrate MRI Safety

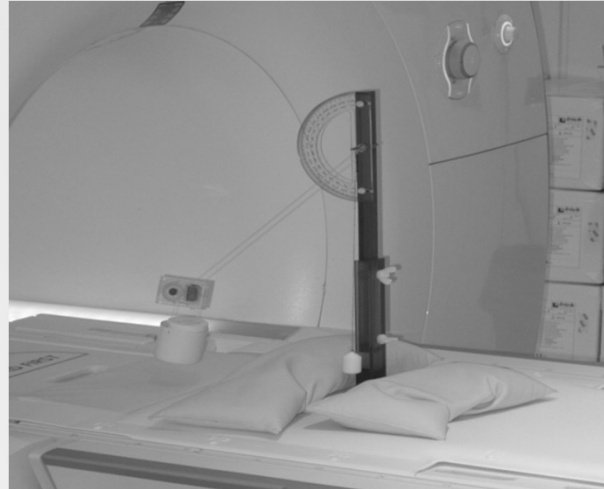- All testing done to ASTM standards
- Some testing done by MED-EL using a clinical scanner
- Some testing done at external test houses



© MED-EL

## MRI Testing with MED-EL Cochlear Implants

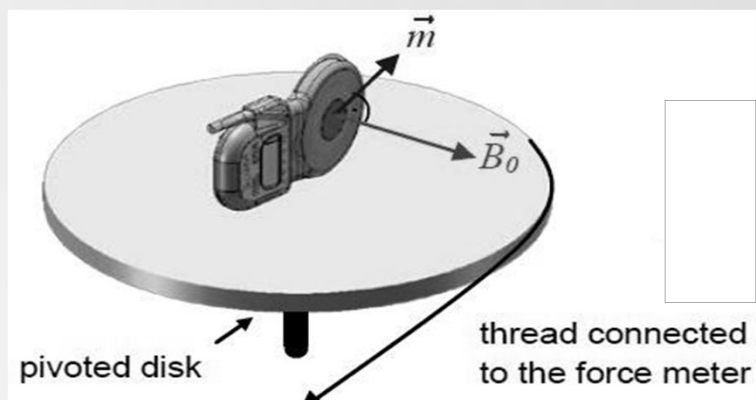
- Force at entrance of scanner vs gravitational force
- If the angle of the attractive force is less than 45 degrees, the implant isn't subjected to a force greater than gravity at the scanner entrance



© MED-EL

## MRI Testing with MED-EL Cochlear Implants

- Torque:
  - Pain
  - Magnet dislocation




© MED-EL

## MRI Testing with MED-EL Cochlear Implants

### Demagnetization

- Magnet weakening occurs within a fraction of a second
- Test before and after
- Repeat x 10
  - Demagnetization isn't linear
  - If orientation angle is unchanged, subsequent scans don't increase the exposure

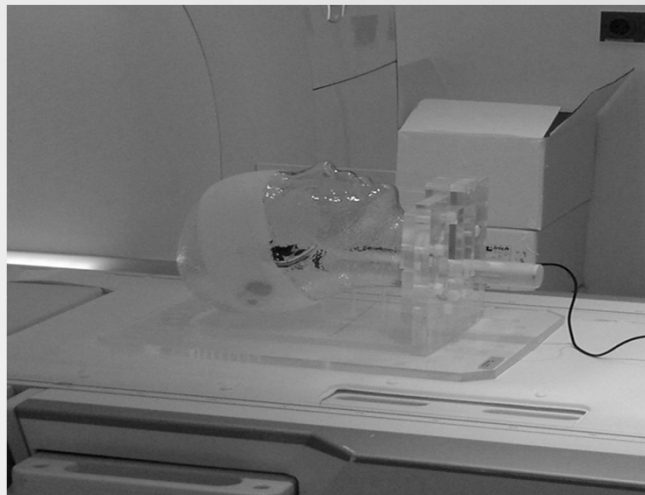


© MED-EL

## MRI Testing with MED-EL Cochlear Implants

### Magnet dislocation

- Glass model of the head
- Implant affixed with bandage (optional when scanning clinically)
- Tiny CCD camera monitors movement to ensure the magnet does not dislocate during the scan

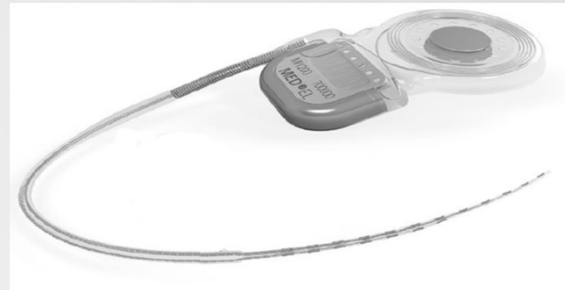

© MED-EL

## MRI Testing with MED-EL Cochlear Implants

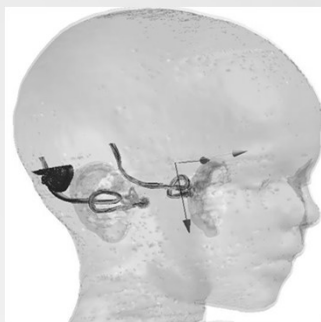

Testing done at external test houses:

- Heating (gradient fields)
- Heating (RF field)
- Unintended stimulation (gradient fields)
- Unintended stimulation (RF field)
- Robustness against MRI sequences
- Image artifacts



© MED-EL

## External Testing: Heating




Not just the magnetic field but a combination of measurement and stimulation together

- Properties of the skull and brain
- Thermal conductivity
- Thermal capacity
- Electrical capacity
- Electrical conductivity
- Variety of electrode trajectories
- Electrode in liquid vs air

© MED-EL

## Magnet Fixation and Removal



Goal: Remove the magnet only when necessary

- Magnet housing has double-conical shape in cross-section
- Magnet fixation disc supports snap-in locking mechanism and force distribution
- Thin, smooth polymer coating of titanium housing to prevent cell adhesion
- Magnet removal only in medial direction

© MED-EL

## Magnet Extraction Force

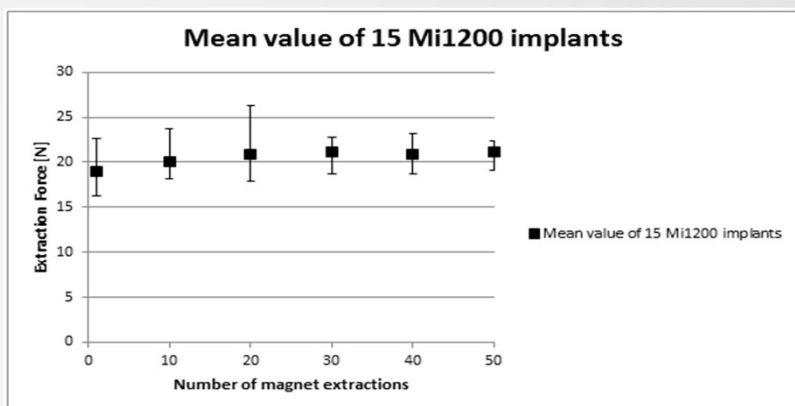




Figure 3: Mean values of magnet extraction forces measured for 15 Mi1200 implants vs number of magnet extractions.

No fatigue even after 50 removals and reinsertions

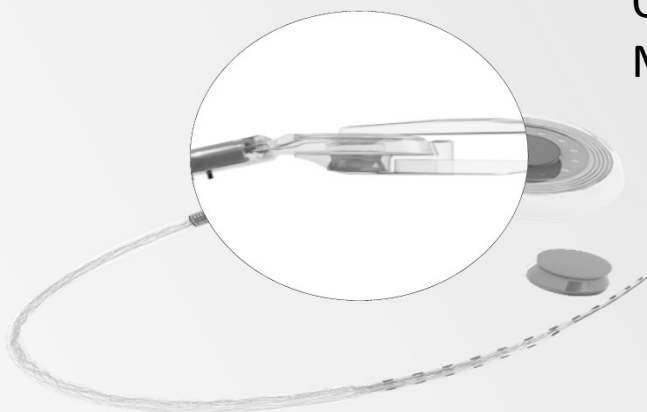


© MED-EL

**MED<sup>EL</sup>**

## SYNCHRONY Cochlear Implant

### Optionally Removable Magnet



- Minimized image distortion on MRI head scans
- Non-Magnetic Spacer available for repeated head scans
- Simple procedure with dedicated instruments

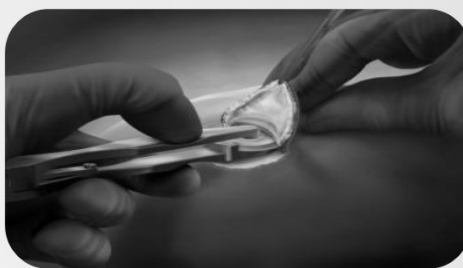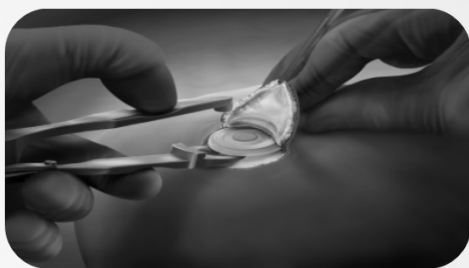
© MED-EL

**MED<sup>EL</sup>**

## Magnet Removal Tool



The magnet is pushed out to the bottom



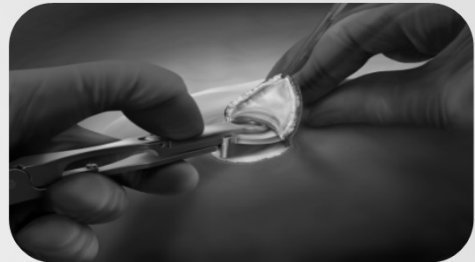© MED-EL

MED<sup>®</sup>EL

## Magnet Insertion Tool



To reinsert the magnet into the implant



© MED-EL

MED<sup>®</sup>EL

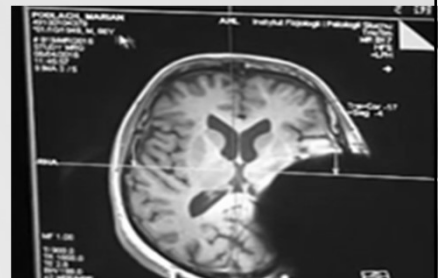
## Magnet Replacement Kit



Non-Magnetic Spacer



Replacement Magnet

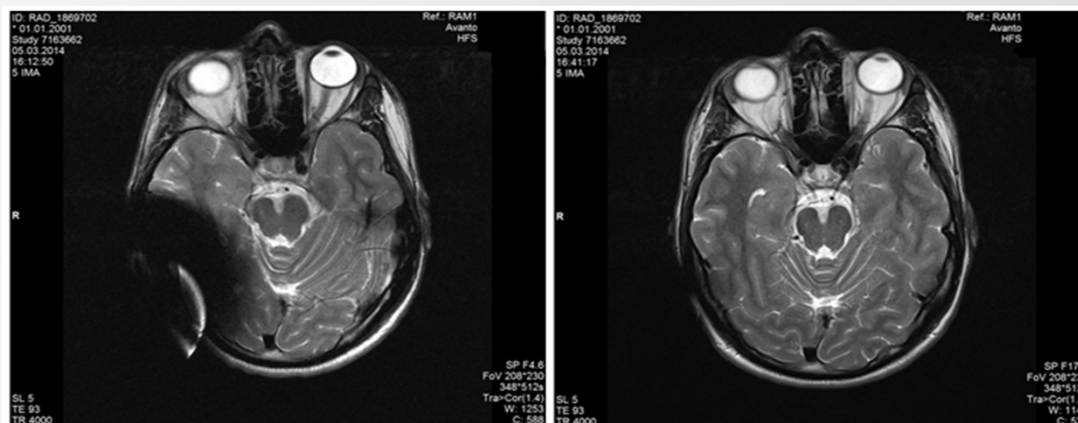


Courtesy Prof Skarzynski, Poland

**Sterile & Single-use**

© MED-EL

## MR Image Artifact at 1.5 Tesla

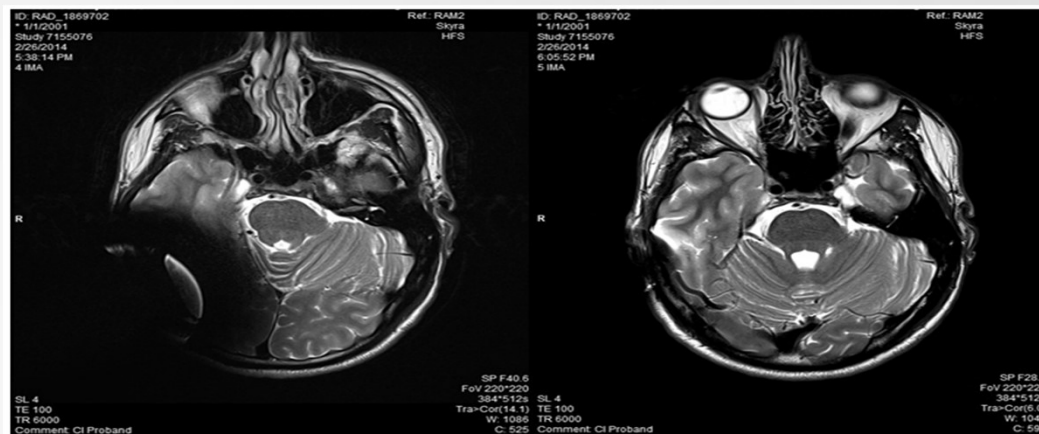


With implant magnet

With non-magnetic spacer

© MED-EL

## MR Image Artifact at 3.0 Tesla



With implant magnet

With non-magnetic spacer

© MED-EL

## MRI Safety Classification of Implants



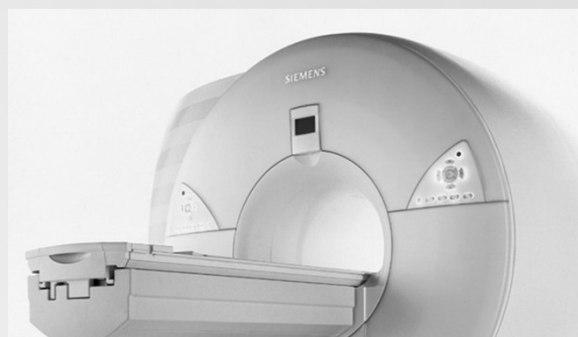MR Safe



MR Unsafe



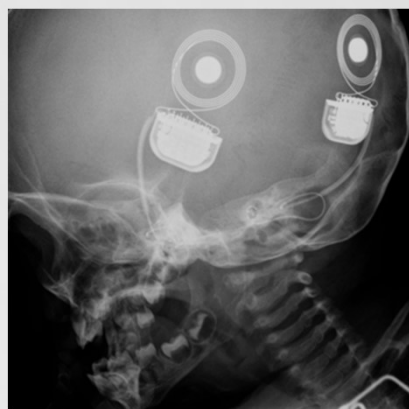MR Conditional



© MED-EL

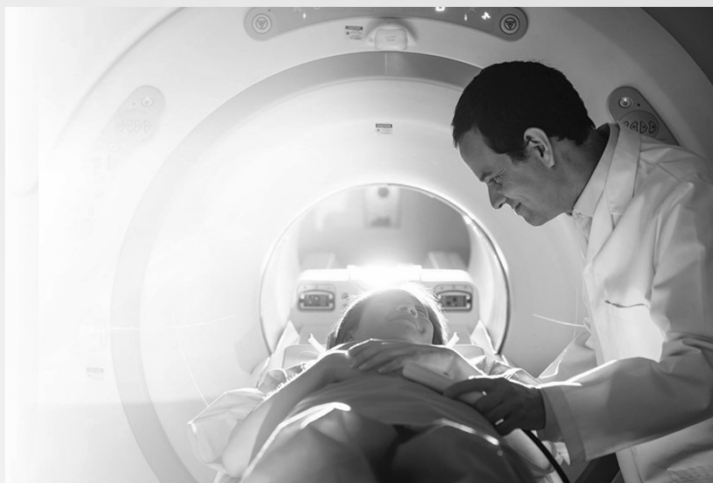## The SYNCHRONY Implant

- **Patented** magnet design
- **FDA approved** and labelled as  
MR conditional at 1.5 and 3.0 Tesla  
(with magnet in place)
- Magnet is optionally removable
- Safe and comfortable for the patient
- Increased image resolution for the physician



© MED-EL

## How Often Does the Magnet Really Need to be Removed?



© MED-EL

## What is the Real Need for Magnet Removal?

- MED-EL “*rough estimate*”: 4-5% of patients may need magnet removal
  - Field experience from earlier days (number of devices implanted vs. number of cases where the implant had to be removed to reduce artifact)
    - A factor of 2-3 added to accommodate for some patients who had CT rather than MRI/removal
  - Global MED-EL ABI experience with NF2 patients who need MRI every 6-12 mos: not one single ABI removed for MRI
  - MRI artifact reduction sequences now available which can reduce artifact by 25-30% may improve efficacy

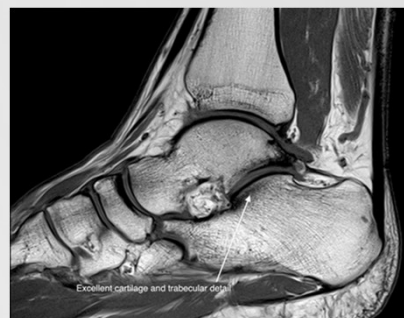ABI not FDA approved in the USA

© MED-EL

## Overview: Brain MRI

in US hospitals (in 2007 and 2010)

Anatomical region	2007	2010	Portion
<b>Brain</b> and Neck	32%	29%	30%
Spine	27%	25%	70%
Extremity	20%	24%	
Vascular (MRA)	9%	8%	
Pelvic & Abdominal	7%	7%	
Breast	2%	4%	
Chest, other cardiac	3%	4%	
Other (Inc. interventional)	1%	1%	



© MED-EL

(GIA; Report linker, US, 2010)

## What is the Real Need for Magnet Removal?

- Lifetime prevalence of neurological disorders requiring MRI in patients with CI = 6.25%
  - MacDonald et al “The incidence and lifetime prevalence of neuro disorders in a prospective community’ Brain, 2000.
  - Could we assume that only some of these cases would require imaging the region of the brain immediately around the implant that overlaps with artifact?

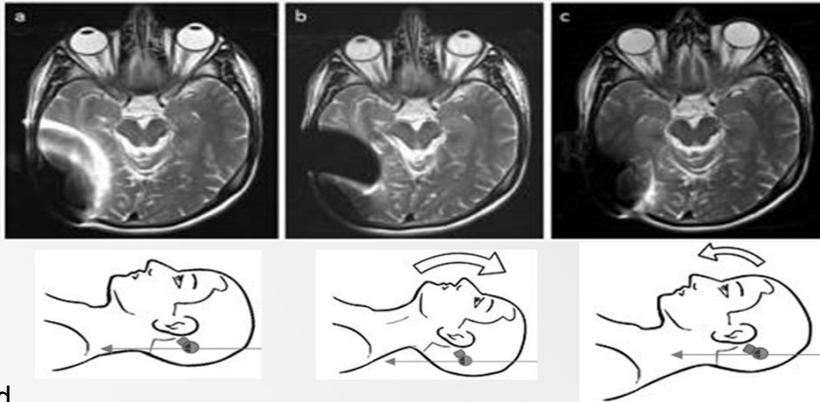


© MED-EL

COVERSTORY I

# MRT bei Patienten mit Cochlea-Implantat – Sicherheit und Optimierung der Bildgebung

v. B. Henninger und Ch. Kremser



head orientation: normal    neck stretched    neck bent

T2w TSE sequence

MRI artifact can be shifted out of slice by head orientation.

**This is only possible with SYNCHRONY!**

© MED-EL

e12 Case Report

THIEME OPEN ACCESS

## Magnetic Resonance Imaging in a Neurofibromatosis Type 2 Patient with a Novel MRI-Compatible Auditory Brainstem Implant

Matthew Shew<sup>1</sup> Judson Bertsch<sup>2</sup> Paul Camarata<sup>3</sup> Hinrich Staecker<sup>1</sup>

J Neurol Surg Rep 2017;78:e12–e14.

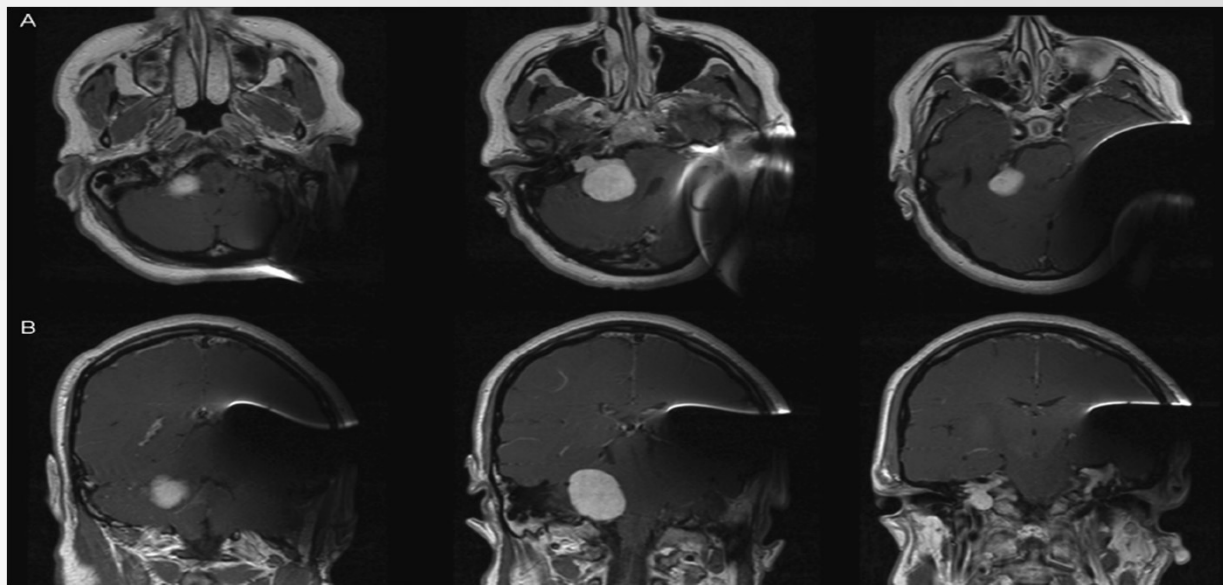
- Case report on 1.5 Tesla MRI in a NF2 Patient with SYNCHRONY ABI in the US
- Synchrony was chosen (FDA exemption) because of MRI need and the high level of MRI safety of SYNCHRONY
- All together 7 MRI scans successfully performed
- Good visibility of tumor in cerebellopontine angle

© MED-EL

Matthew Shew<sup>1</sup> Judson Bertsch<sup>2</sup> Paul Camarata<sup>3</sup> Hinrich Staecker<sup>1</sup>

J Neurol Surg Rep 2017;78:e12–e14.

**MED<sup>®</sup>EL**



© MED-EL

**MED<sup>®</sup>EL**

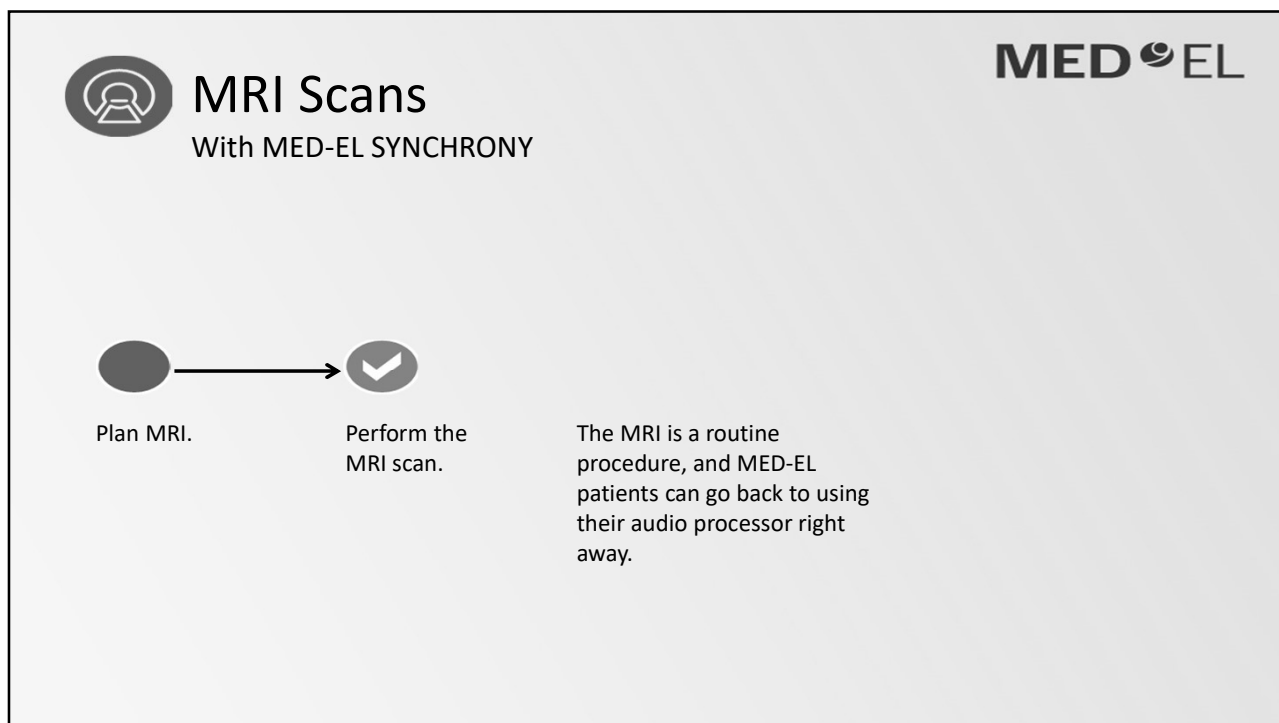
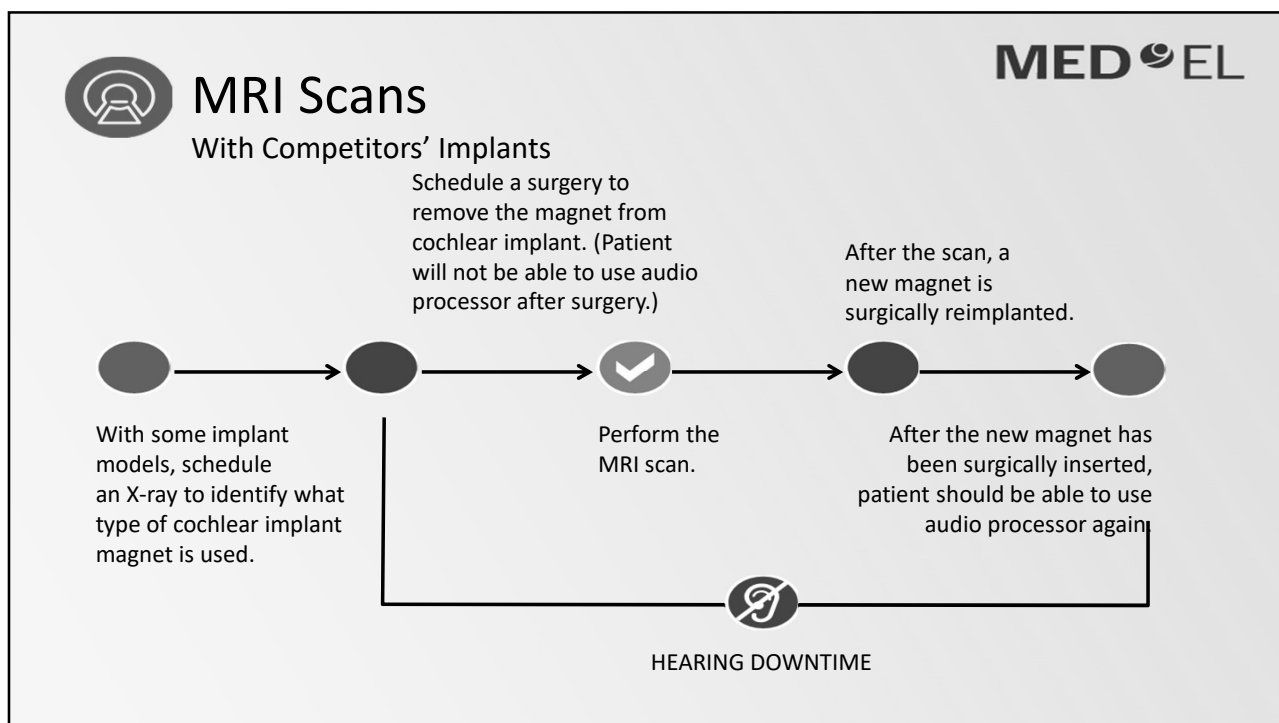
## What Are the Ramifications for the Patient?

Magnet removal and replacement

- Two surgeries
- Insurance preauthorization for both
- Need to order/purchase a replacement magnet
- Necessary each time a repeat MRI is ordered
- Scar tissue development around multiple incisions



© MED-EL





## MRI Scans

With MED-EL SYNCHRONY

**MED-EL**

No Surgery  
No Discomfort  
No Hearing Downtime



## MRI Scans

With MED-EL SYNCHRONY

**MED-EL**

No other cochlear implant brand is  
FDA-approved for MRI at 3.0 Tesla without  
requiring additional surgery  
to remove the magnet.



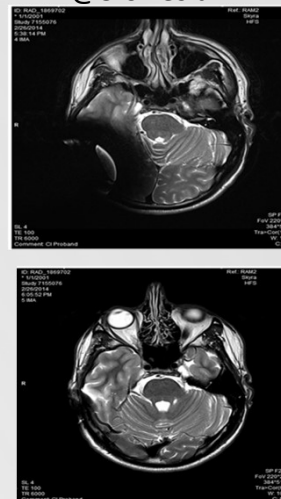
**MED-EL**

## SYNCHRONY Implant

Feedback & field experience June 2017:

- 38 months since market introduction, 27 months on US market
- Very positive clinical experience
- Not a single magnet has been weakened in MRI
- Not a single magnet dislocated in the course of an MRI or due to a mechanical impact over the implant
- So far only four cases of SYNCHRONY magnet removal for MRI, one completed here in the US

@3.0 Tesla



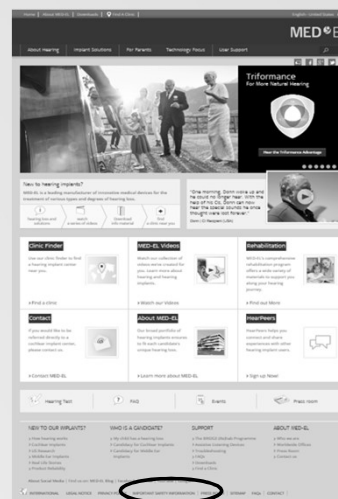© MED-EL

**MED-EL**

## Where to Easily Find Scanning Instructions

- *Important Safety Information* link, found at the bottom of all MED-EL web pages

About Social Media | Find us on: MED-EL Blog | Facebook | Twitter | YouTube | Google+  
 INTERNATIONAL | LEGAL NOTICE | PRIVACY POLICY | **IMPORTANT SAFETY INFORMATION** | PRESS ROOM | SITEMAP | FAQs | CONTACT |  
 © 2017 MED-EL

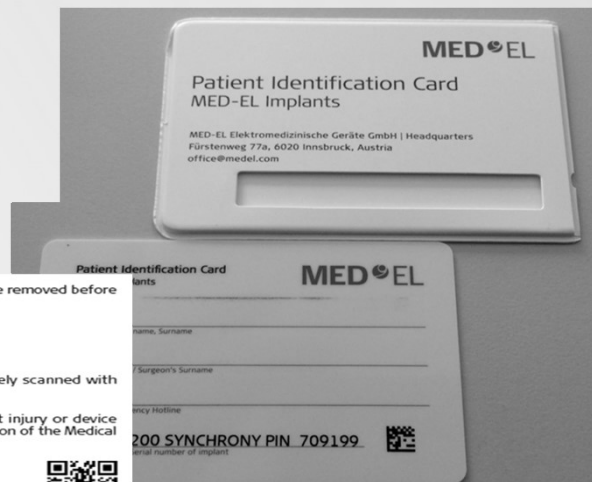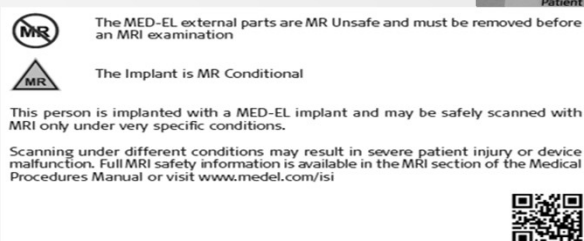


© MED-EL

## Where Can MRI Safety Info Be Found?

### – Product labeling

- Medical Procedures Manual
- Patient ID Card
- User Manual





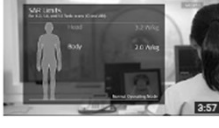


© MED-EL



## YouTube Instructional videos

Go to the MED-EL YouTube Channel, or

Search for “MRI MED-EL”

	<b>Why is MRI Safety So Important for Cochlear Implants?</b> MED-EL 8 months ago • 3,341 views <a href="http://www.medel.com/int/cochlear-implants-mri-safety">http://www.medel.com/int/cochlear-implants-mri-safety</a> Why is MRI safety so important for people with cochlear implants? Hint: A ...
	<b>MRI Scans With Cochlear Implants—MED-EL</b> MED-EL Professionals 8 months ago • 768 views <a href="http://www.medel.com/isi">http://www.medel.com/isi</a> Step-by-step radiography instructions on how to perform a 1.5 Tesla MRI scan on patients with a ...
	<b>MRI Scans With SYNCHRONY Cochlear Implant—MED-EL</b> MED-EL Professionals 8 months ago • 751 views <a href="http://www.medel.com/isi">http://www.medel.com/isi</a> Step-by-step radiography instructions on how to perform a 1.5 or 3.0 Tesla MRI scan on patients with a ...
	<b>CI2016 - Dr. Kevin Brown on MRI and Cochlear Implants</b> MED-EL 1 year ago • 572 views <a href="http://www.medel.com">http://www.medel.com</a> Dr. Kevin Brown discusses cochlear implants and MRI compatibility. He specifically highlights the ...
	<b>The MED-EL SYNCHRONY Cochlear Implant</b> MED-EL 2 years ago • 4,915 views The SYNCHRONY Cochlear Implant from MED-EL is part of the SYNCHRONY Cochlear Implant System. It is built on the proven ...

© MED-EL



- How likely are you to stress the importance of MRI compatibility with cochlear implant candidates?
  - Very likely
  - Somewhat likely
  - Not likely

Do you feel more confident discussing MRI issues with recipients and candidates?

- Yes
- No

© MED-EL

